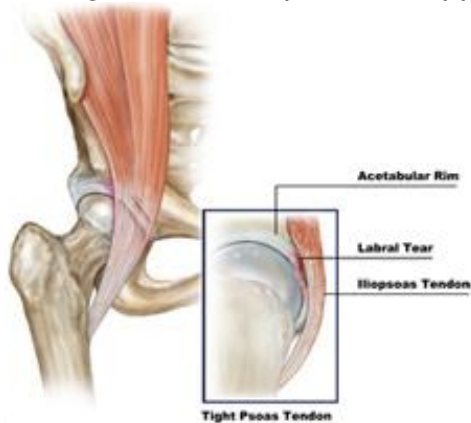


Snapping tendons

The things that snap around the hip joint aren't coming from the joint themselves. They more likely come from tendons around the hip that snap with certain motions. The two most common things to snap around the hip are the iliopsoas tendon and the iliotibial band.

Iliopsoas tendon

This tendon forms from two muscles that come from the pelvis (iliacus and psoas muscles) and join together to insert on the top of the thigh bone and work to flex and rotate the hip. The tendon can sometimes rub over the hip socket and cause a snapping sensation that is many times audible from across the room. The problem can be diagnosed with a good physical exam and usually an MRI scan. The MRI is usually done in this case to look for damage to the labrum and cartilage from the repeated snapping over the rim of the hip socket.



When conservative measures fail, the problem can be alleviated using hip arthroscopy. Traditionally the tendon would be released off the bone using an open technique. This was complicated by significant hip flexor muscle weakness and sometimes formation of abnormal bone in traumatized tissue. Addressing the problem using hip arthroscopy allows for a minimally invasive approach. The tendon can be “lengthened” instead of “cut.” The weakness in hip flexion is temporary as the tendon heals in a lengthened position and the snapping is eliminated.

Iliotibial Band (ITB)

The band is formed from two powerful hip extensor muscles – starts at the rim of the pelvis and extends to the knee. The band glides over a prominence on the top of the thigh bone (femur). Many times this band can irritate the fluid sac between the bone and overlying soft tissue causing hip bursitis. Activity modification, oral medications, physical therapy and occasionally injections can help alleviate most symptoms related to the ITB. Rarely do symptoms persist requiring surgical intervention. The snapping from this broad tendon can be both seen and heard. When severe enough it sometimes gives the appearance of one's hip socket "popping out of joint." If all else fails, minimally invasive hip arthroscopy can be used to debride the inflamed bursal tissue and lengthen the band causing the problem.

